

COMPLICATIONS OF SWENSON'S PROCEDURE IN HIRSCHSPRUNG'S DISEASE- A HOSPITAL BASED 5 YEAR STUDY

Kinkar Mahanta¹, Manoj Gogoi²

¹Assistant Professor, Department of Paediatric Surgery, Assam Medical College and Hospital, Dibrugarh, Assam, India.

²Assistant Professor, Department of Paediatric Surgery, Assam Medical College and Hospital, Dibrugarh, Assam, India.

ABSTRACT

BACKGROUND

Hirschsprung's Disease (HD) is the commonest cause of functional intestinal obstruction in children and poses challenges to paediatricians and paediatric surgeons in resource- limited countries. This disease results from failure of ganglion cells to migrate cephalocaudally through the neural crest during 4th to 12th weeks of gestation, causing an absence of ganglion cells in all or part of the colon. This study describes the clinical characteristics and management of this disease in our setup and highlights the challenges associated with the care of such patients.

METHODS

This was a prospective observational study of children from neonatal age group up to 10 years who were histologically diagnosed and treated for HD at our institute between March 2013 and February 2018.

RESULTS

A total of 63 patients (M: F= 2.5: 1) with a median age of 3.2 months (IQR of 0.17–10.00 months) were studied. Almost all patients presented with intestinal obstruction followed by constipation in 93.65% cases. We did not encounter enterocolitis. All the patients underwent Swenson's definitive pull-through. Postoperative complications were very minimal. Mortality rate was 12.69%. During the follow-up period results of Swenson's procedure was found to be good.

CONCLUSIONS

HD is the commonest cause of functional intestinal obstruction in children and in older children presenting with constipation. This disease is associated with high morbidity and mortality especially in those older children who present late and when the disease becomes complicated. Early diagnosis and treatment are the cornerstones of the management of this malady.

HOW TO CITE THIS ARTICLE: Mahanta K, Gogoi M. Complications of swenson's procedure in hirschsprung's disease- a hospital based 5 year study. J. Evolution Med. Dent. Sci. 2019;8(21):1690-1694, DOI: 10.14260/jemds/2019/372

BACKGROUND

Hirschsprung's disease (HD) is a common paediatric surgical emergency encountered and it poses a great challenge to both the paediatricians as well as the paediatric surgical team. HD is caused by an absence of ganglion cells in the submucosa and muscularis propria in the distal bowel and extending proximally for variable distances, due to arrest in the cranio-caudal migration of neural crest cells during the embryonic life.^[1-3] That the distal colon is the actual abnormality and it was initially forwarded by Tittel,^[4] in 1901 in a child with Hirschsprung's disease. Its incidence is 1 in 5000 live births. The causes of HD is multifactorial and the diagnosis is made during the newborn period only, but in the developing world late presentation are even found.

Rectal biopsy is the gold standard for diagnosing Hirschsprung's disease, it shows the absence of ganglion cells and presence of hypertrophied nerve fibres. First described by Swenson et al in 1959.^[5] Suction rectal biopsy developed by Bodian in 1960,^[6] which greatly facilitated in the diagnosis by obviating the need for general anaesthesia.

'Financial or Other Competing Interest': None.
Submission 25-03-2019, Peer Review 09-05-2019,
Acceptance 17-05-2019, Published 27-05-2019.
Corresponding Author:

Kinkar Mahanta,
 Assistant Professor,
 Department of Paediatric Surgery,
 Assam Medical College and Hospital,
 Dibrugarh-786002, Assam, India.
 E-mail: kinkarm69@gmail.com
 DOI: 10.14260/jemds/2019/372



Swenson and Bill^[7] are credited with the first successful surgical procedure for this disease, although different pull-through procedures like Duhamel^[8] and Soave^[9] have been described since then. Currently all these procedures are done with laparoscopic assistance or through a transanal route without abdominal scars.^[10]

In a developing country like India, Hirschsprung's disease is still a diagnostic and therapeutic enigma. Although work on this subject has been done elsewhere in India,^[11] little work has been done in this north-eastern state of India. Hence this study was carried out to determine the clinical characteristics and management of HD at our centre.

METHODS

This was a prospective observational study. All cases attending the PSOPD of Assam Medical College & Hospital (AMCH) on Wednesday or referred as an emergency cases, during the period March 2013 to February 2018. The study population included all new-born cases referred by the New-Born Intensive Care Unit (NICU) and Paediatric Medicine Ward during this period. Neonates and up to 10 years were included in this study.

Patients meeting the Inclusion criteria were included in the study and after obtaining a written informed consent from the parents/guardian.

Inclusion Criteria

1. All full-term neonate who fail to pass meconium within 48 hours of life with or without abdominal distension.
2. Any infant with h/o constipation, abdominal distension, poor feeding, vomiting, failure to thrive (FTT).

3. Children \geq 1 year with constipation, abdominal distension, vomiting, failure to thrive.
4. All cases with transition zone on Barium enema.
5. Rectal biopsy positive for HD.

Exclusion Criteria

1. Any children with inconclusive radiological and negative histopathological findings.
2. Children older than 12 years of age.

Diagnosis was confirmed by history, clinical evaluation, barium enema and/or rectal biopsy. Most of the cases had a well-defined transition zone on contrast enema which was further substantiated by a seromuscular biopsy undertaken at the time of laparotomy for a transverse loop colostomy. Older children had undergone rectal biopsy besides a contrast enema. Biopsy was also taken at the time of pull-through from the wall of the pulled-through segment. Routinely haemoglobin estimation, serum electrolytes, serum creatinine, blood grouping and cross matching was done.

Pre-operatively all patients who presented with features of intestinal obstruction were resuscitated with intravenous fluids for correction of dehydration and dyselektrolytemia and started on Broad spectrum antibiotics. After stabilising the patients all were subjected to decompressing colostomy. Biopsy was taken from the edge of the colostomy also.

Surgical Technique

All patients in this study underwent a three staged procedure involving colostomy, definitive abdomino-pelvic pull-through and colostomy closure. One patient was on ileostomy for Total colonic aganglionosis. Patients who presented with constipation were also subjected to colostomy to decompress the dilated colon. In 5 cases, we did a sigmoid levelling colostomy as they presented with hugely distended abdomen and faecalomas and in whom a two staged procedure sufficed. The age of colostomy ranged from 3 days to 10 years.

Swenson's procedure was adopted in all the cases where the aganglionic segment was resected and ganglionic segment was pulled down and anastomosed to the anus.^[7] Age at definitive surgery ranged from 6 months to 11 years. The abdominoperineal pull-through procedure, after induction of general anaesthesia, was done in the supine position with the pelvis elevated at the edge of the operating table and lower limbs set apart and strapped on two small gauze rolls put below the knees.

Specimens were obtained from the pulled through bowel wall so as to ensure that a ganglionated segment has been used in the pull-through procedure. Third generation Cephalosporin along with Amikacin and Metronidazole were used in all the cases and at least for five days.

Post-operatively oral feeding was instituted in all cases on 2nd post-operative day except those children who underwent the two staged surgery whom we kept nil orally for 5 days. In a few inconsolably crying children we even started breast feeding on the very first postoperative evening as we had a protecting colostomy.

After the pull-through operation we followed an anal dilatation programme using Hegar's dilator after 2 weeks from the pull-through for ensuring a safe patency of the anastomotic site. Colostomy closure was done after 2-3 months of the pull-through procedure.

Intraoperative blood loss was minimal, and transfusion were given in those followed up neonatal cases who had pre-operative haemoglobin of 9 gm% only. Operative duration varied from 90 minutes to 150 minutes. Hospital stay varied from 7 days to 18 days.

Data of each patient was entered in a proforma designed for the study. The study variables included age at presentation, sex, clinical features, type of decompression done and complications if any, proximal level of aganglionosis, age at definitive surgery and complications if any, age at colostomy closure. Other information recorded were length of hospitalization, mortality, need for second surgery and bowel function at follow-up. Patients were followed up at 3 months, 6 months and thereafter annually or till death whichever is earlier.

Ethical Consideration

Prior approval was obtained from the Institutional Ethics Committee (H) of Assam Medical College and Hospital before commencement of the study and a written informed consent was taken from the parents/guardian before enrolling into the study.

Statistical Analysis

Data are presented in terms of percentages and median along with IQR. Statistical significance was tested by Fisher's exact test.

RESULTS

The age at presentation varied from 3 days to 10 years with a median of 3.2 months, (IQR 0.17-10.00 months). 45 (71.43%) were males and 18 (28.57%) were females, with a male female ratio of 2.5: 1

At presentation, failure to pass meconium (49.21%) was the most common presentation followed by abdominal distention in neonates. Older children presented with Abdominal distention (60 cases) and Constipation (59 cases). There were no patients with enterocolitis.

More than 48 cases (76.2%) had haemoglobin levels less than 9 gm/dl. Electrolyte abnormalities in the form of hypokalaemia and hyponatremia were found in 19 (30.2%) and 14 (22.2%) patients respectively. Plain X-ray of abdomen (erect) was done in all cases and showed gaseous distension with multiple air-fluid levels in 31 cases. Barium enema showed classic transition zone in 32 cases (50.7%). Histopathological examination (HPE) confirmed the diagnosis in all the patients.

62 (92.1%) patients in our study had colostomy before pull-through. One (1.6%) patient had an ileostomy for total colonic aganglionosis. Fifty-seven (91.9%) patients underwent right transverse colostomy and remaining five (8.1%) underwent sigmoid levelling colostomy. The median age at colostomy was 2.13 months with range from 3 days to 10 years. The duration from colostomy to definitive pull-through was 1.17 to 17.93 months with a median of 6.17 months, (IQR 0.25-9.88 months).

Definitive pull-through was done in 62 patients with one patient undergoing total colectomy and ileo-anal pull through. The median age at definitive pull-through was 6.17 months with a range from 3 days to 10 years. Colostomy closure was done in 62 cases at the end of the study period and one is awaiting definitive pull-through.

Age Group	Sex		Total	
	Male	Female	Number	Percentage (%)
Neonate	23	8	31	49.21
1-6 m	5	3	8	12.70
>6-12 m	12	2	14	22.22
1-5 years	1	1	2	3.17
>5 years	4	4	8	12.70
Total	45	18	63	100.00

Table 1. Distribution of Children with Age and Sex

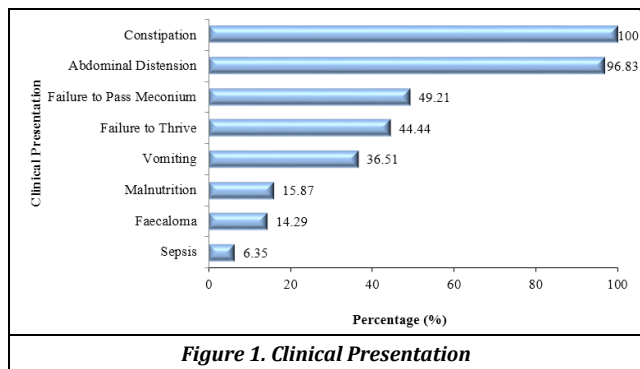


Figure 1. Clinical Presentation

Site	Number (n)	Percentage (%)
Rectosigmoid	31	49.21
Sigmoid	29	46.03
Rectum	3	4.76

Table 2. Site of Transition Zone

Post-Operative Complications	Number (n)	Percentage (%)
Colostomy Related (n=26):		
Peristomal Skin Excoriation	26	100
Colostomy Prolapse	6	23.1
Colostomy Retraction	1	3.8
Definitive Pull-Through Complications (n=6):		
Surgical Wound Infections	6	100
Wound Dehiscence	1	16.6
Soiling	1	16.6
Colostomy Closure Related (n=11):		
Surgical Site Infection	8	72.7
Ugly Scar	5	45.4

Table 3. Postoperative Complications

Age Group	Number (n)	Mortality		p Value
		Number (n)	Percentage (%)	
<1 month (Neonate)	31	5	16.13	0.4741
≥ 1 month	32	3	9.38	
TOTAL	63	8	12.70	

Table 4. Mortality

The mortality between the children of <1 month and ≥ 1 month was not considered to be statistically significant (p > 0.05).

Associated Anomalies	Number(n)	Percentage (%)
Congenital Heart Disease	9	14.29
Renal Abnormality	5	7.94
Down Syndrome	1	1.59

Table 5. Distribution of Associated Anomalies

The commonest associated anomaly found in our study was congenital heart disease (14.29%).

The time interval from definitive pull-through to colostomy closure ranged from 4.33 months to 136.77 months with a median of 10.00 months, (IQR 7.83-19.68 months).

Treatment Outcome

Distribution of patients according to post-operative complications (N=26). Complication rate was 41.2%.

DISCUSSION

In this study majority of our patients were within one year of life, 31 patients (49.21%) being in neonatal period and 18 patients (28.57%) within infancy. A high index of clinical suspicion coupled with efficient referrals from neonatology and paediatric ward probably reasons for this stark contrast in incidence with developed countries,^[12] although our place is a part of a developing country. Mabula et al have reported their majority of patients after one year of life.^[13]

This study also showed that males were more afflicted by the disease as reported in the literature.^[14] In our study we found males to be affected more than females.

Clinical presentation in our study showed a mixed pattern. 31 being neonates and the rest with late presentation. This was attributed to delayed referral by the peripheral practitioners who treat them for constipation with different laxatives and elixirs. The delayed referrals were in conformity to other studies.^[15,16]

Hirschsprung’s disease is associated with cardiovascular, urologic, and gastrointestinal abnormalities. One of the most common chromosomal abnormality associated with the disease is Down syndrome which has been found to occur in 4.5% to 16% of children with HD.^[17,18] In this study there was one patient with Down’s syndrome amongst the referred cases. The diagnosis of HD in a patient with Down’s syndrome is difficult and other causes like hypothyroidism must be excluded.^[19] High mortality due to cardiac malformations associated with Down’s syndrome may be one cause of low incidence in this series.

Rectal biopsy is the gold standard in confirming HD.^[20] As suction biopsy was not available in our centre, we had to resort to full thickness rectal biopsy under General Anaesthesia.

The main principle of surgery in Hirschsprung’s disease is removal of the aganglionic segment and anastomosing a normal ganglionated segment which was first described by Swenson and Bill.^[7] Later on, Duhamel^[8] and Soave^[9] described the retro-rectal and endorectal pull-through respectively. Although these three techniques have been widely used in various centres by different surgeons in management of HD with variable outcomes, yet the choice of technique a surgeon uses is dependent on his training, available resources and the mode of case presentation. In agreement with other developing countries ^[21] we stuck with the Swenson’s pull-through mostly. Duhamel’s pull-through was not practised as our patients were from the lower socio-economic strata and could not afford GI stapler needed in the final stage of anastomosis. Hand sewn anastomosis was not possible due lack of OT time and limited manpower. Although these time tested staged procedures are associated with multiple hospital admissions and exposure to anaesthesia affecting daily wage earners of the families, social ostracization in our setup and the potential for complications associated with a colostomy we could not do away with it and as has been the practice in other developing countries as well. A single staged procedure like Transanal Endorectal pull through would definitely obviate these problems but then in our series the cases, presenting lately with hugely dilated

colons with faecalomas forced us to anticipate failure only to attempt a single stage pull through.

Complications and outcome in the surgery of HD mainly revolves around two factors – Continence and Bowel function in terms of daily motion or constipation. Complication rates in our study were surprisingly minimal and manageable too. Fecal soiling and that too mostly nocturnal was found in our series. One of these patients who had nocturnal swelling was a patient with Down's syndrome, and the others we hope will improve with time and with dietary restrictions.

The facilities to measure the sphincter function by anorectal manometry was not there in our centre yet from the history and clinical examination of the patients and the happiness of the parents and guardians as well most of our patients were found to be continent. Bowel functions too were negligible with most of our patients having two to three motions daily.

Mortality rates in our series was 12.7 %. This varied from 1% to 10% in developed and developing nations. Menezes et al^[22] reported 3.5% whereas Wildhabers^[23] had 12%. Mortality rates as high as 23.8% have been reported from Nigeria.^[16]

Managing a child with Hirschsprung's disease in a developing country like us is very challenging. Poverty, Social issues, Limited manpower and facilities, late referrals in children are the vexing problems that compels us to stick to a staged procedure at this moment. With improvement in the aforesaid areas a proper and scientific approach can be expected. Lack of suction and froze-section biopsies and delayed referrals in infants and children were the limitations in our study and needs to be addressed.

CONCLUSIONS

Although surgery for Hirschsprung's disease has progressed in developed countries from open multiple staged techniques to single staged minimally invasive techniques, we have miles to go. Hopefully with timely referrals and help from the Government sector through financial support and increase in human resources, we look forward to embracing the state-of-the-art treatment techniques in the near future.

ACKNOWLEDGEMENT

The authors would like to thank Mr Hiranya Saikia, Biostatistician of Assam Medical College & Hospital.

REFERENCES

- [1] Colombani PM, Foglio RP, Skinner MA, et al. Principle and practice of paediatric surgery. 4th edn. Philadelphia: Lippincott Williams and Wilkins 2005;2:1348-63.
- [2] Tiltelbaum DH, Coran AG, Martucciello G, et al. Hirschsprung's Disease and related neurotransmusclar disorders of the intestine. In: O' Neill JA Jr, Fonkalsrud EW, Coran AG, et al. eds. Pediatric surgery. 6th edn. Philadelphia: Mosby-Elseiver 2006;(2):1514-59.
- [3] Meza-Valencia BE, De Lorimier AJ, Person DA. Hirschsprung's disease in the U.S. associated Pacific Islands: more common than expected. Hawaii Med J 2005;64(4):96-8.

- [4] Tittel K. Uber eine angeborene Missbildung des Dickdrmes. Wien Klin Wochenschr 1901;14:903-7.
- [5] Swenson O, Fisher JH, Gherardi GJ. Rectal biopsy in the diagnosis of Hirschsprung's disease. Surgery 1959;45(4):690-5.
- [6] Bodian M. Pathological aids in the diagnosis and management of Hirschsprung's disease. In: Dyke SC, edr. Recent advances in clinical pathology. 3rd series. London: Churchill Livingstone 1960: p. 384.
- [7] Swenson O, Bill AH Jr. Resection of rectum and rectosigmoid with preservation of the sphincter for benign spastic lesions producing megacolon: an experimental study. Surgery 1948;24(2):212-20.
- [8] Duhamel B. A new operation for the treatment of Hirschsprung's disease. Arch Dis Child 1960;35(179):38-9.
- [9] Soave F. A new surgical technique for the treatment of Hirschsprung's disease. Surgery 1964;56:1007-14.
- [10] Georgeson KE, Cohen RD, Hebra A, et al. Primary laparoscopic-assisted endorectal colon pull-through for Hirschsprung's disease: a new gold standard. Ann Surg 1999;229(5):678-83.
- [11] Shifa S, Kamaleshwari K. How common is Hirschsprung's disease at the tertiary care center in Western Tamilnadu: a cross sectional study. Journal of Evolution of Medical and Dental Sciences 2015;4(92):15782-5.
- [12] Archibong AE. Pattern of aganglionic megacolon in Calabar, Nigeria. S Afr Med J 2002;92(8):642-4.
- [13] Mabula JB, Kayange NM, Manyama M, et al. Hirschsprung's disease in children: a five year experience at a University teaching hospital in northwestern Tanzania. BMC Research Notes 2014;7:410.
- [14] Hukkinen M, Koivusalo A, Merras-Salmo L, et al. Postoperative outcome and survival in relation to small intestinal involvement of total colonic aganglionosis. J Pediatr Surg 2015;50(11):1859-64.
- [15] Ameh EA, Chirdan LB. Neonatal intestinal Obstruction in Zaria, Nigeria. East Afr Med J 2000;77(9):510-3.
- [16] Nasir AA, Adeniran JO, Abdur-Rahman LO. Hirschsprung's disease: 8 years of experience in a Nigerian teaching hospital. J Indian Ass Peditr Surg 2007;12(2):68-71.
- [17] Caniano D, Teitelbaum D, Qualman SJ. Management of Hirschsprung's disease in children with trisomy 21. Am J Surg 1990;159(4):402-4.
- [18] Goldberg EL. An epidemiological study of Hirschsprung's disease. Int J Epidemiol 1984;13(4):479-85.
- [19] Hackam DJ, Reblock K, Barsdale EM, et al. The influence of Down's syndrome on the management and outcome of children with Hirschsprung's disease. J Pediatr Surg 2003;38(6):946-9.
- [20] Kessmann J. Hirschsprung's disease: diagnosis and management. Am Fam Physician 2006;74(8):1319-22.
- [21] Bandre E, Kabore RA, Quedraogo I, et al. Hirschsprung's disease: management problem in a developing country. Afr J Pediatr Surg 2010;7(3):166-8.

[22] Menezes M, Corbally M, Puri P. Long-term results of bowel function after treatment for Hirschsprung's disease: a 29-year review. *Pediatr Surg Int* 2006;22(12):987-90.

[23] Wildhaber BE, Teitelbaum DH, Coran AG. Total Colonic Hirschsprung's disease: a 28-year experience. *J Pediatr Surg* 2005;40(1):203-7.